



VA Mid-Atlantic Health Care Network

MIRECC

*Mental Illness
Research,
Education and
Clinical Center*



**Post Deployment Mental Health
VISN 6**

Windows to the Brain: Coronal Anatomy 1

Prefrontal-Subcortical Circuits Cortical Association Tracts

Katherine Taber, PhD, FANPA

MIRECC Assistant Director - Education

Research Health Scientist

W.G. "Bill" Hefner VAMC, Salisbury NC

Research Professor, Div Biomedical Sci

Edward Via College of Osteopathic Medicine

Robin Hurley, MD, FANPA

MIRECC Associate Director - Education

ACOS/Research and Education Service Line

W.G. "Bill" Hefner VAMC, Salisbury NC

Professor, Psychiatry and Radiology

Wake Forest University School of Medicine

Source: <http://www.mirecc.va.gov/visn6/Tools-Tips.asp>

Use of text, images and other content are subject to the following terms and conditions:

Fair Use Is Permitted

Fair use of copyrighted material includes the use for non-commercial educational purposes, such as teaching, scholarship, research, criticism, commentary, news reporting, and other content. Unless otherwise noted, users who wish to download or print text and image files from this Web site for such uses may do so without the VISN 6 MIRECC's express permission, provided that they comply with the following conditions:

The content may only be used for personal, educational or non-commercial purposes;

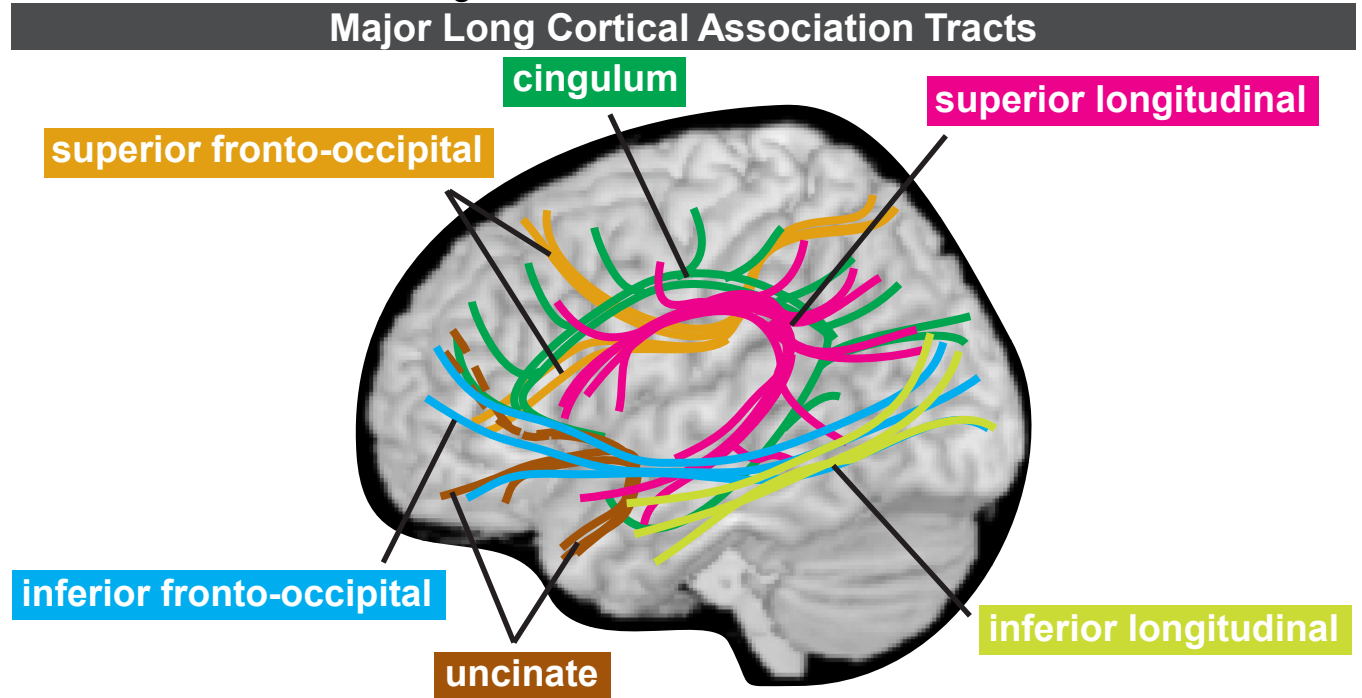
Users must always specifically cite the author(s) and source of the content every time the material is used, as they would for material from any printed work;

None of the content may be altered or modified.

Warranty

By downloading, printing, or otherwise using text and image files from this website, users agree and warrant that they will limit their use of such files to fair use.

Right side of each section: Major cortical association tracts are labeled and color-coded to match the figure below. *



Brief guide to neuropsychiatric symptoms associated with injury to tract.

superior fronto-occipital (subcallosal) fasciculus
orbital & medial prefrontal cortex ↔ parietal cortex

akinetic mutism; disordered initiation & preparation of speech movements; transcortical motor aphasia; anomia & reduction of spontaneous speech with normal articulation

<p>cingulum - short fibers cingulate cortex ↔ frontal, parietal, occipital & temporal cortex</p>	<p>cingulum - long fibers frontal cortex ↔ temporal cortex</p>
---	---

Anterior - lack of emotional affective response to pain; anxiety; OCD; depression; panic; akinetic mutism **Posterior** - impaired integration of visuospatial & memory processing

superior longitudinal (arcuate) fasciculus
frontal cortex ↔ parietal, occipital & temporal cortex

R - left hemispatial neglect; **L** - conduction aphasia (fluent aphasia with impaired repetition, mostly preserved language comprehension); ideational apraxia (can't carry out skilled movements and/or commands); depression; speech arrest; anomia; **Posterior** - transcortical sensory aphasia (impaired auditory comprehension, intact repetition & fluent speech)

uncinate fasciculus
orbital & polar prefrontal cortex ↔ anterior temporal cortex

deficits in retrieval of past information: **R** - episodic context-dependent memory, personal experiences, autobiographical; **L** - context-free memory, general knowledge of facts

inferior fronto-occipital fasciculus
ventrolateral & dorsolateral prefrontal cortex ↔ posterior temporal & occipital cortex

R>L - impaired orienting of attention; visual recognition abnormalities; **R+L** - impaired pursuit eye movements; inaccurate reaching under visual guidance; impaired motion perception; **R or R+L** - impaired seeing/selecting in crowds; impaired spatial relations; visual agnosia & poor visual memory; impaired recognition of places & directions to get there; getting lost

inferior longitudinal fasciculus
temporal pole ↔ occipital cortex

disorders in recognition (visual agnosia) impaired visual recent memory; **R or R+L** - impaired face recognition (prospagnosia), visual object agnosia, visual hypoemotionality if cue presented visually; **R+L or L>R** - contralateral deficit in color vision (hemiachromatopsia); **L-bilateral** misnaming of objects presented by touch (tactoverbal dysfunction)

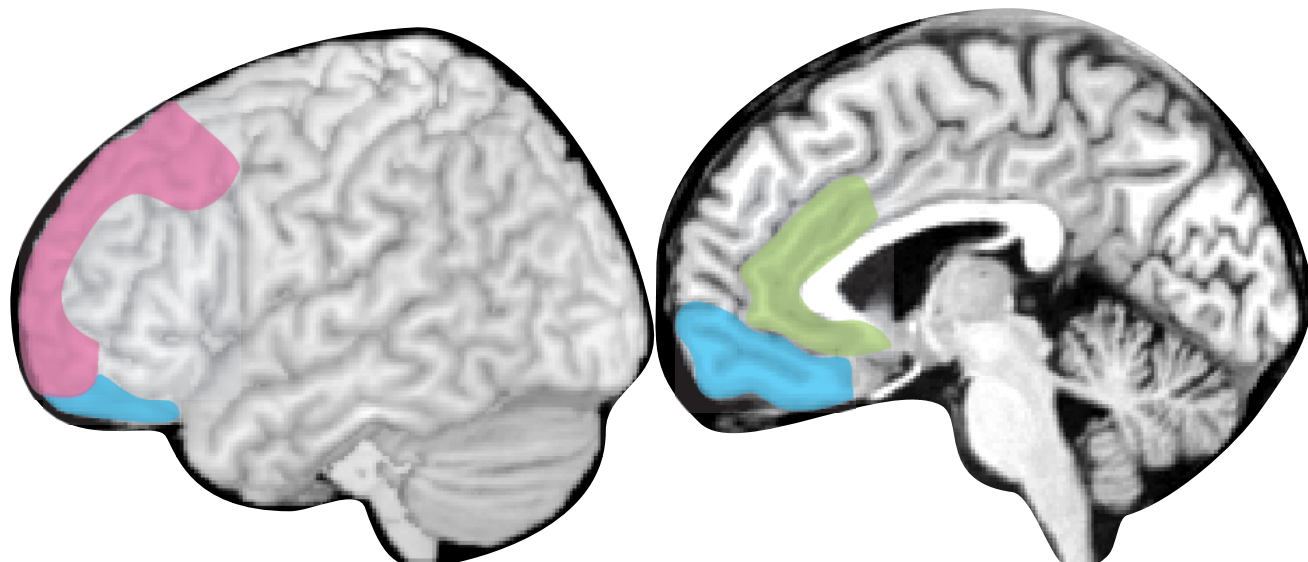
*Taber KH, Hurley RA. J Neuropsychiatry Clin Neurosci 2007;19(2):100-104.

Left side of each section: Tracts involved in major prefrontal cortical-subcortical circuits and major subcortical structures are labeled and color-coded to match the figures below.*

Major Prefrontal - Subcortical Circuits

In psychiatry, the prefrontal cortex is generally divided into three principal areas. Each area has reciprocal connections with subcortical structures that form cortico-subcortical circuits.

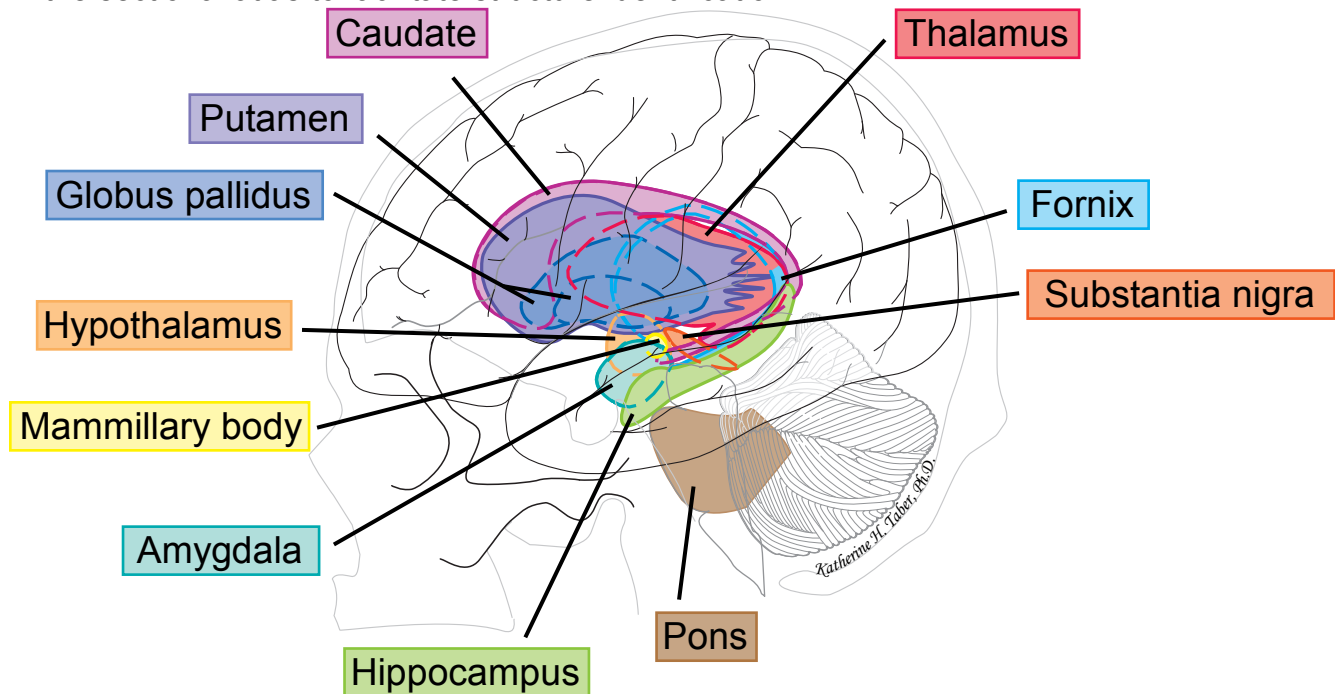
<p>Dorsolateral circuit mediates executive functions such as organization, planning & attention</p>	<p>Orbitofrontal circuit mediates socially appropriate behavior, impulse control & empathy</p>	<p>Anterior cingulate circuit produces motivation by balancing the inhibitory input of the supplemental motor area with its own stimulus that supports wakefulness & arousal</p>
--	---	---



*Bonelli RM, Cummings JL. Dialogues Clin Neurosci. 2007;9(2):141-51.

Major Subcortical Structures

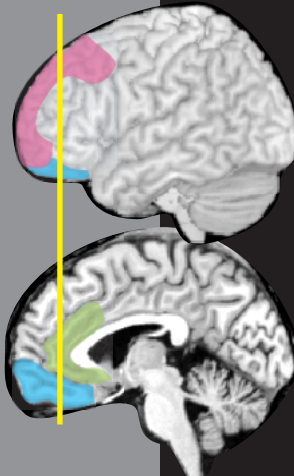This cartoon of a lateral view of the brain and skull shows the approximate positions and configurations of the major subcortical structures. The colors assigned in this figure are used in the sectional atlas to facilitate structure identification.*



*Naumescu I, Hurley RA, Hayman LA, Taber KH. Int J Neuroradiol 1999; 5(1): 51-59.

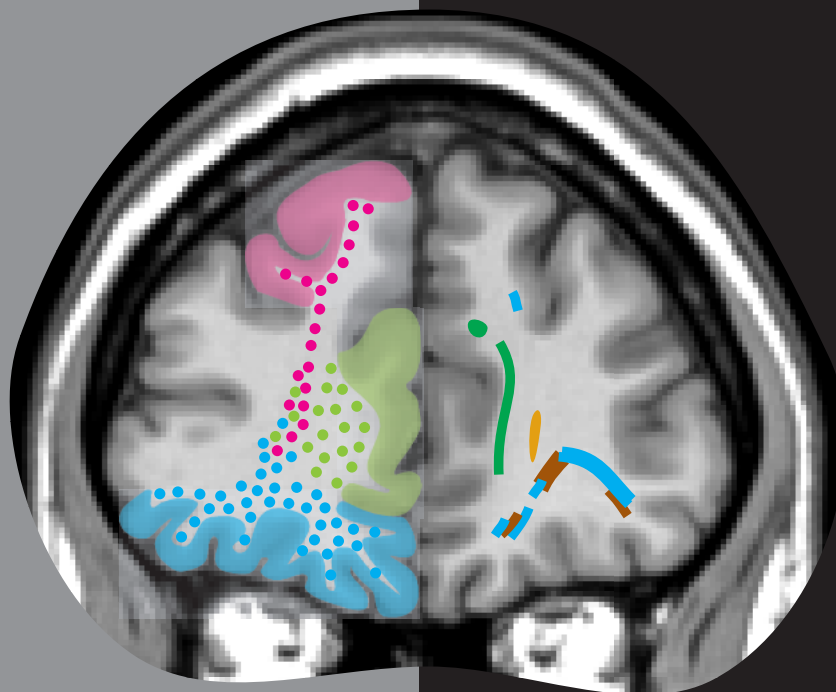
Major Prefrontal-Subcortical Circuits

- Dorsolateral
- Anterior Cingulate
- Orbitofrontal



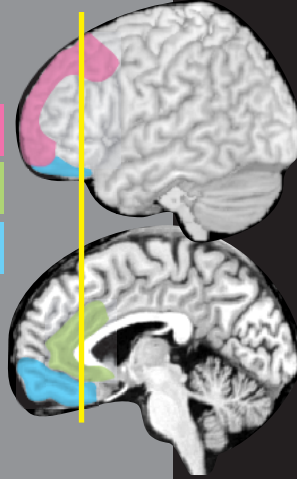
Major Cortical Association Tracts

- cingulum
- superior fronto-occipital
- inferior fronto-occipital
- uncinate
- superior longitudinal
- inferior longitudinal



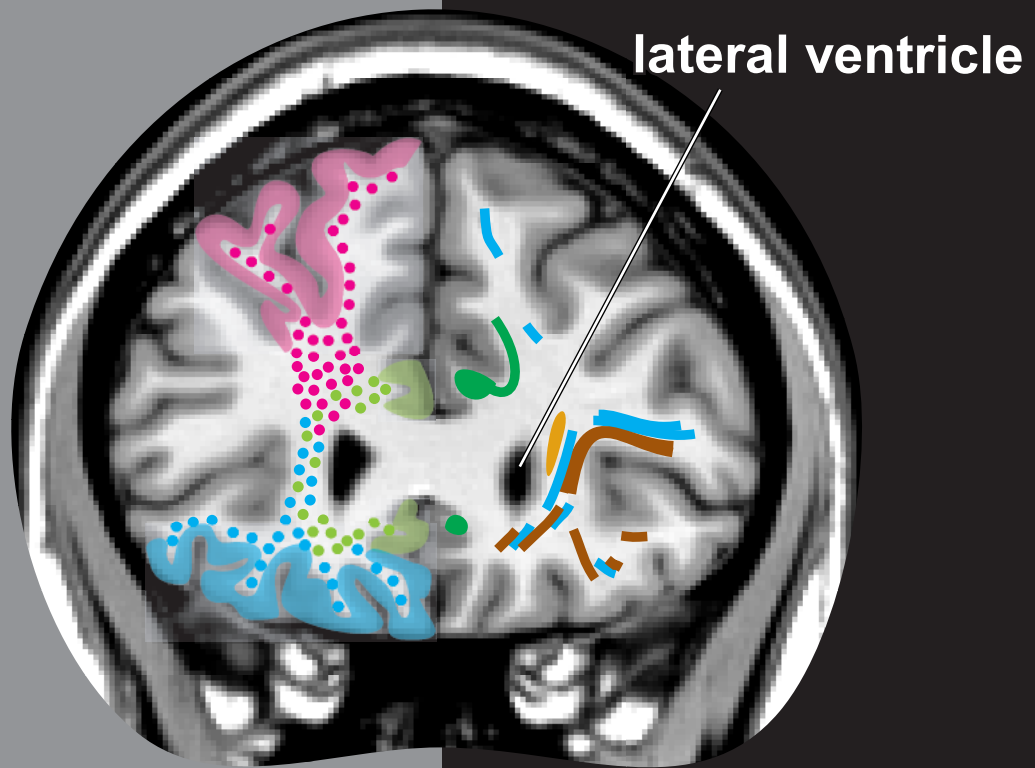
Major Prefrontal-Subcortical Circuits

- Dorsolateral
- Anterior Cingulate
- Orbitofrontal



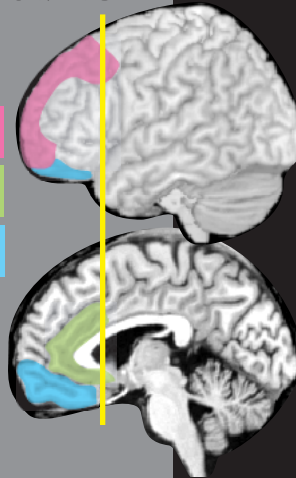
Major Cortical Association Tracts

- cingulum
- superior fronto-occipital
- inferior fronto-occipital
- uncinate
- superior longitudinal
- inferior longitudinal



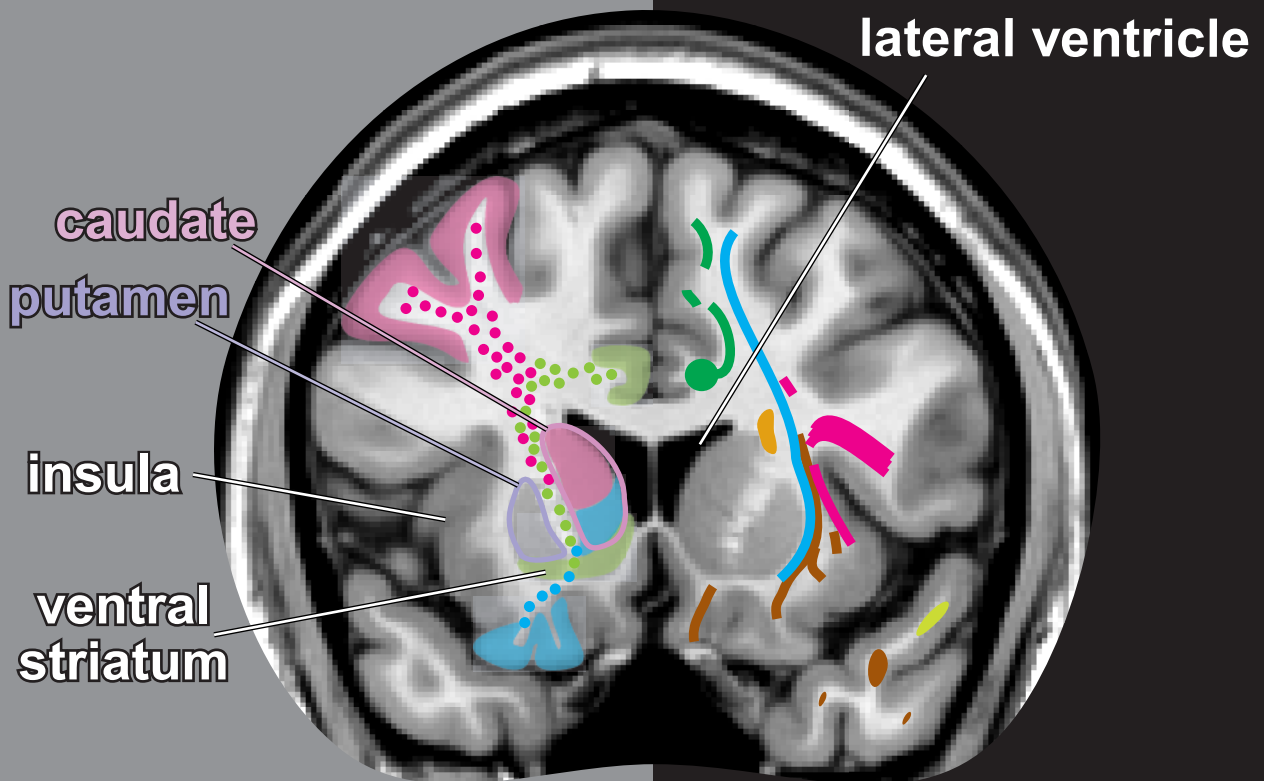
Major Prefrontal-Subcortical Circuits

- Dorsolateral
- Anterior Cingulate
- Orbitofrontal



Major Cortical Association Tracts

- cingulum
- superior fronto-occipital
- inferior fronto-occipital
- uncinate
- superior longitudinal
- inferior longitudinal

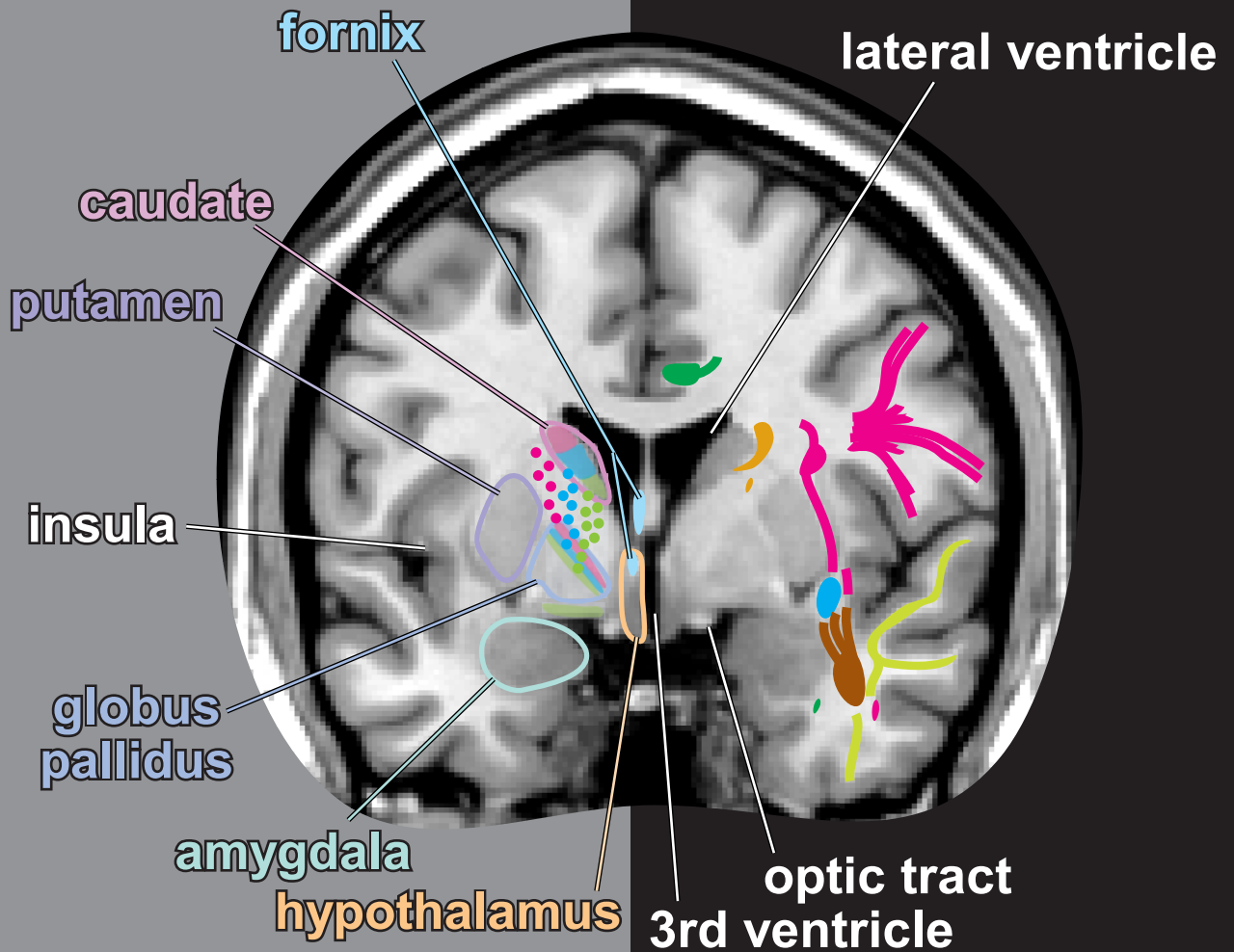
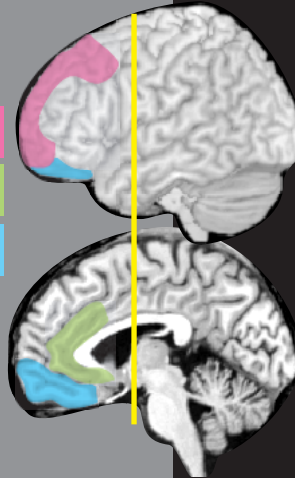


Major Prefrontal-Subcortical Circuits

- Dorsolateral
- Anterior Cingulate
- Orbitofrontal

Major Cortical Association Tracts

- cingulum
- superior fronto-occipital
- inferior fronto-occipital
- uncinate
- superior longitudinal
- inferior longitudinal

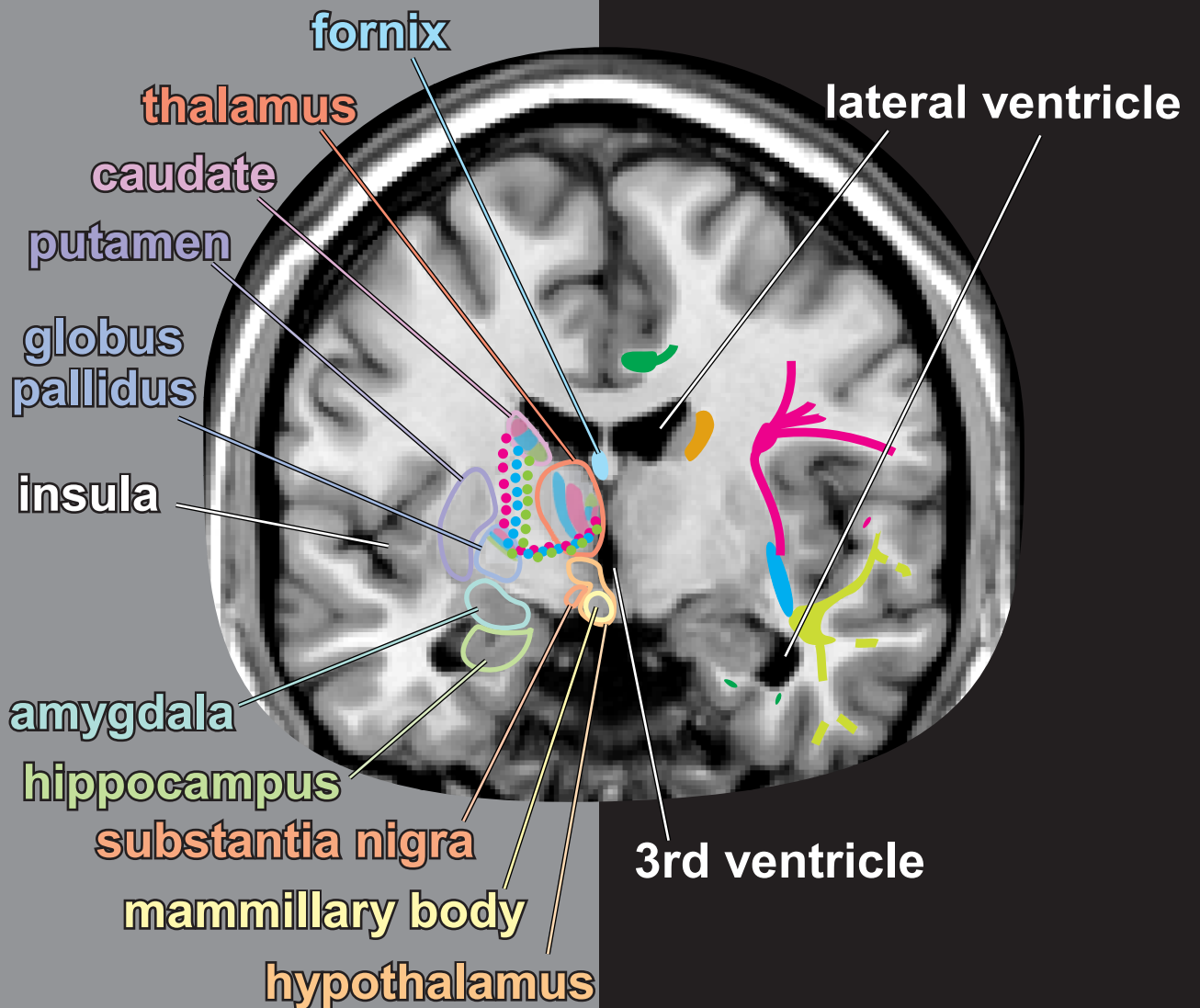
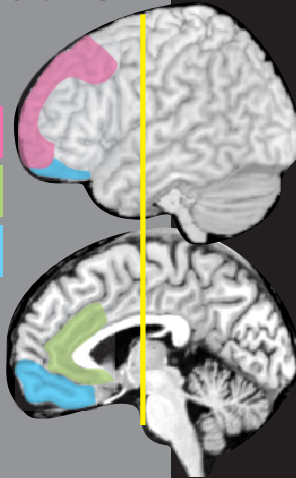

Major Prefrontal-Subcortical Circuits

- Dorsolateral
- Anterior Cingulate
- Orbitofrontal

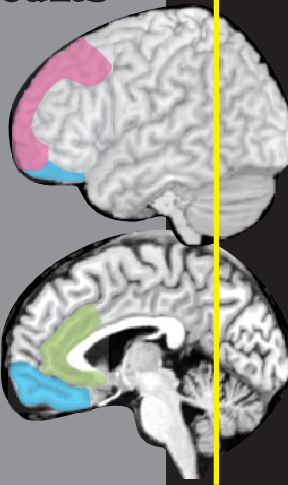
Major Cortical Association Tracts

- cingulum
- superior fronto-occipital
- inferior fronto-occipital
- uncinate
- superior longitudinal
- inferior longitudinal



Major Prefrontal-Subcortical Circuits

- Dorsolateral
- Anterior Cingulate
- Orbitofrontal



Major Cortical Association Tracts

- cingulum
- superior fronto-occipital
- inferior fronto-occipital
- uncinate
- superior longitudinal
- inferior longitudinal

lateral ventricle

